

# Geographic Atrophy-Like Induced Model in Nanopigs

Marianna Bacellar-Galdino, Brandon Ossont, Nathaniel Pappenhagen, Alexander Walz, Simone Iwabe  
<sup>1</sup>Altasciences Preclinical Scranton, Scott Township, PA, USA

Abstract # 2544-B0257

[Click here to listen to the recorded poster presentation](#)

## INTRODUCTION

- Geographic atrophy (GA) is one of the signs of dry age-related macular degeneration (AMD) . It refers to the retinal pigment epithelium (RPE) cell death that precedes photoreceptor atrophy, which leads to blindness<sup>1, 2</sup>.
- The Nanopig is an ideal animal model due to its eye's similarities to the human eye. The pig retina has a rod photoreceptor-dominant periphery and a cone photoreceptor-dominant visual streak<sup>3</sup>.
- The objective of this study was to develop a large animal model of GA in Nanopigs injecting NaIO<sub>3</sub> subretinally.

## METHODS

- 3 Nanopigs (Sinclair Research, Altasciences) received a bilateral subretinal injection of NaIO<sub>3</sub> (0.05 mg/mL) on Day 1.
- An ophthalmic exam (OE), fundus image, confocal scanning laser ophthalmoscopy (cSLO), optical coherence tomography (OCT), and fluorescein angiography (FA) were performed immediately after induction on Day 1 and on Days 3, 8, and 14.
- Retinal thickness (inner, outer, and total retina) was measured using ImageJ and analyzed by ANOVA.

## RESULTS

- All six eyes received a successful 100 µL injection of NaIO<sub>3</sub> subretinally, with blebs observed at all time points during Oes and fundus imaging.
- The retina was reattached by Day 3, as observed in the OCT images.
- FA showed increased signal on Day 3 and marked bleb area on Days 8 and 14, suggesting localized RPE damage.
- There was a significant decrease in the total thickness of the retina ( $p < 0.0001$ ), the inner retina ( $p < 0.0001$ ), and the outer retina ( $p < 0.0001$ ) in the bleb area over the 14 days of the study.
- The total retinal thickness decreased by 53% (mean: from 319.39 µm at pre-dosing to 151.00 µm on Day 14,  $p < 0.0001$ ).
- The inner retina in the bleb area was decreased by 28% (mean thickness: from 145.36 µm at pre-dosing to 105.75 µm on Day 14,  $p = 0.0014$ ).
- The outer retina in the bleb area lost 74% of its thickness (mean: from 174.02 µm at pre-dosing to 45.25 µm at Day 14,  $p < 0.0001$ ).
- Retinal thickness outside of the bleb area showed no changes in any layers or in total retinal thickness by Day 14 ( $p = 0.4033$ ).
- Inflammatory-like cells were observed in the vitreous and retina in OCT.

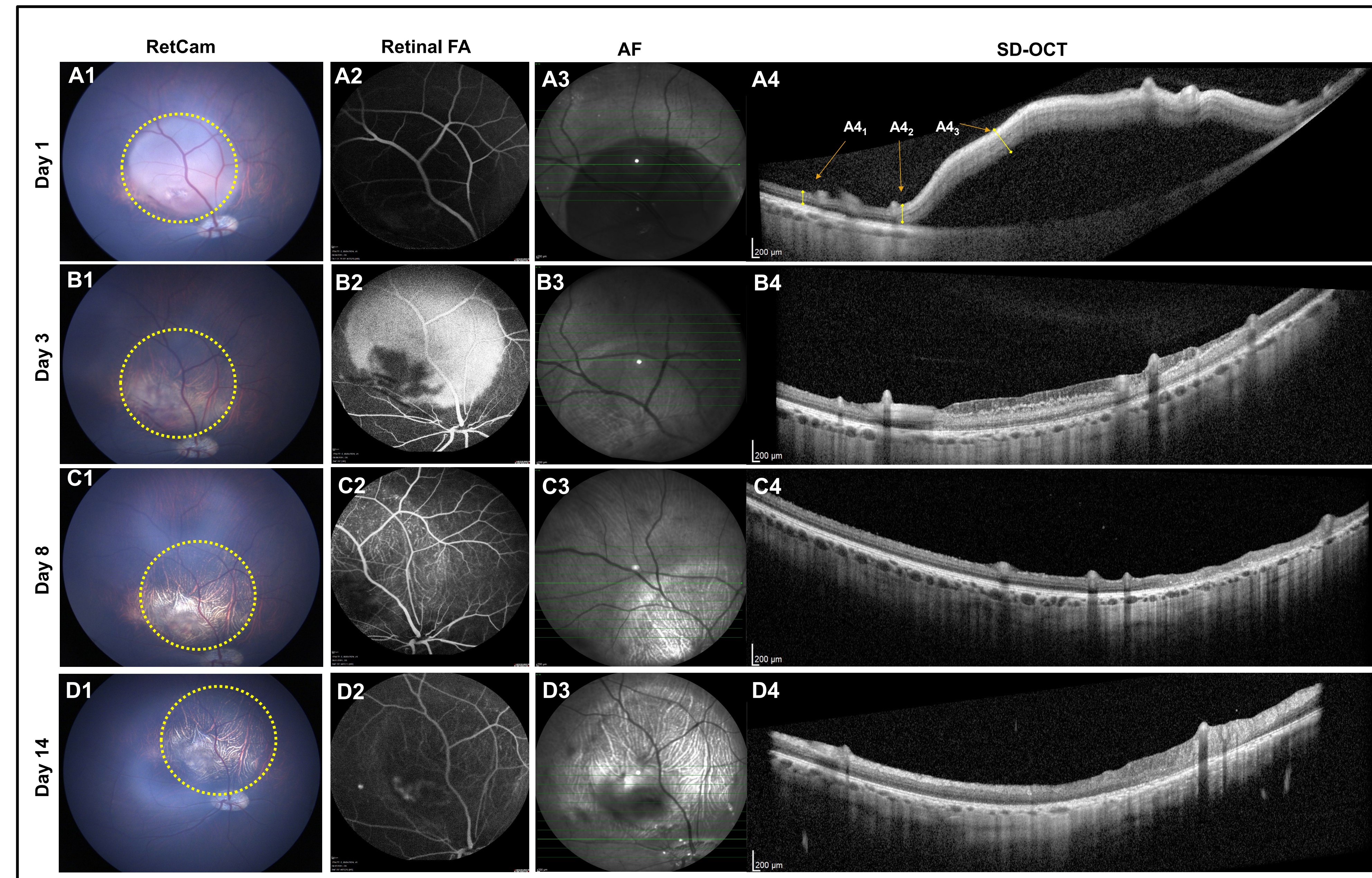


Figure 1. *In Vivo* Images Shows Alterations in Retinal Morphology

Representative fundus images of one animal showing observed retinal changes following subretinal NaIO<sub>3</sub> injection. **A1, B1, C1, D1**: Fundus color images of sub-retinal bleb. **A2, B2, C2, D2**: RFA images showing blebs and their associated degeneration as discolored areas in the superior retina that were fluorescent, and in IR (**A3, B3, C3, D3**). **A4, B4, C4, D4**: IR/SD-OCTs show the bleb and surrounding retina. **A4** shows examples of the undamaged (**A4<sub>1</sub>**), transition (**A4<sub>2</sub>**), and the bleb (**A4<sub>3</sub>**) regions that were measured for the retinal thickness in yellow. Yellow circles represent bleb/damaged area.

## CONCLUSION

- Subretinal injection of NaIO<sub>3</sub> created a GA-like lesion in Nanopigs.
- The significant thinning of the outer retina indicates a loss of photoreceptors similar to GA in dry AMD.
- This localized retinal damage mode will allow for the screening and development of new therapies and drug candidates for dry AMD.

## REFERENCES

- Hanus J. Cell Death and Discovery 2016; 16054.
- Koh A. Journal of Photochemistry & Photobiology 2019; 111514.
- McCall, M. A. Cold Spring Harbor Perspectives in Medicine; 14:a041296.

## Acknowledgments

- The staff at Altasciences Preclinical Scranton for animal care support.
- CR: None

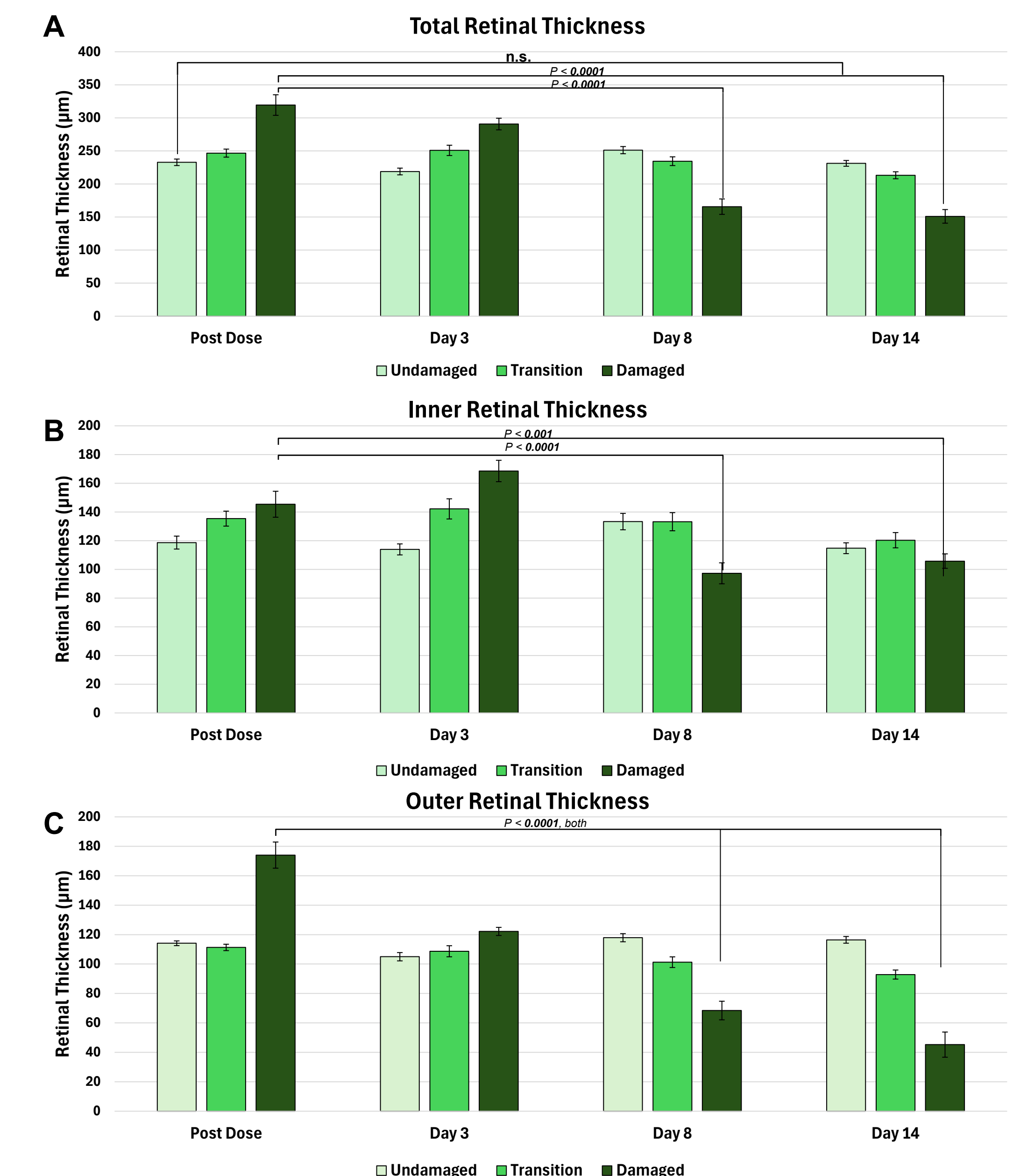


Figure 2. Retinal Thickness in the NaIO<sub>3</sub> Induced GA Model in Nanopigs

Retinal thickness increases in the bleb immediately post-dose and then decreases to thinner than undamaged retina over two weeks. Total retinal thickness was measured (A), as well as the thickness of the inner retina and outer retina (B & C, respectively). There was no significant difference in the retinal thickness in the undamaged areas of the retina ( $p = 0.40$ )